

## INSTITUTIONAL BASED STUDY OF SURFACE EPITHELIAL OVARIAN TUMORS

Vikas Pandey<sup>1</sup>, Ramesh Chandra Arya<sup>2</sup>, Vishal Kulkarni<sup>3</sup>, Shankar Marshal Toppo<sup>1</sup>

Received : 16/07/2023  
Received in revised form : 20/08/2023  
Accepted : 02/09/2023

**Keywords:**

Epithelial ovarian tumors, benign, borderline, malignant, serous, mucinous, seromucinous, brenner, endometrioid, clear, and undifferentiated.

Corresponding Author:

**Dr. Vikas Pandey,**

Email: vikas.pandey09@gmail.com

DOI: 10.47009/jamp.2023.5.5.118

Source of Support: Nil,

Conflict of Interest: None declared

*Int J Acad Med Pharm*  
2023; 5 (5); 609-612



<sup>1</sup>Assistant Professor, Department of Pathology, Rajmata Shirimati Devendra Kumari Singh Deo Government Medical College, Ambikapur, Chhattisgarh, India

<sup>2</sup>Director Professor, Department of Pathology, Rajmata Shirimati Devendra Kumari Singh Deo Government Medical College, Ambikapur, Chhattisgarh, India

<sup>3</sup>Associate Professor, Department of Pathology, Rajmata Shirimati Devendra Kumari Singh Deo Government Medical College, Ambikapur, Chhattisgarh, India

### Abstract

**Background:** Ovarian cancer is one of the most frequent cancers in female patient. Surface epithelial tumors form two third of all ovarian neoplasm. Epithelial ovarian tumor is no single disease but is composed of a diverse group of tumors that can be classified based on distinctive morphologic and molecular genetic features. The aim of study is assessing pattern of Histopathology subtype of surface epithelial ovarian tumors and correlate these finding with varies clinicopathological variables. **Materials and Methods:** Surface epithelial ovarian tumour specimen were included in this study received in the department of pathology. **Result:** There were 65 cases of surface epithelial tumors. most common subtype is serous cyst adenoma. No malignant surface epithelial ovarian tumor seen during study period. Two borderline tumor were found one seromucinous and one mucinous category. No malignant epithelial ovarian tumors cases seen during study. Unilateral ovarian pathology seen in most of the patients. **Conclusion:** The overall diagnosis of ovarian neoplasm mainly depends on the histopathological typing. Age, size, and other clinical parameters helps to guide treatment correlation with subtypes based on recent histopathological classification.

## INTRODUCTION

Ovarian tumors is one of the most frequent tumors in female patient. Ovarian cancer was estimated to be third most common cancer among Indian women and eighth common overall of all cancer cases.<sup>[1]</sup> Ovulation, growth factors, cytokines, and environmental agents may play a role in the initiation and progression of ovarian cancer. Familial predisposition has been noticed in approximately 5-10% of cases. The risk for developing ovarian cancer is increased fourfold in women with affected first degree relative.<sup>[2,3]</sup> The low survival is due to the lack of symptoms in early stages. Despite development of optimal surgical techniques an The most significant risk factor for developing ovarian cancer is age. The incidence of ovarian cancer has been reported to be low but with a steady increase in the age standardize prevalence rate of ovarian cancer by 3% per year in different state registries over a period of time.<sup>[4]</sup> The most significant risk factor for developing ovarian cancer is age. Ovarian tumor can be classified in to benign, borderline, malignant and metastatic. 2020 WHO classification of ovarian tumor separates these tumors on the basis of tissue of origin: Surface

epithelial (65%), Germ cell (15%), sex cord -stromal (10%), Metastasis. Surface epithelial tumors Epithelial ovarian cancers are further divided into 7 histologic subtypes: serous, endometrioid, mucinous, clear cell, brenner, seromucinous, and undifferentiated.<sup>[5]</sup> The low survival is due to the lack of symptoms in early stages. Symptoms are frequently very subtle and may include: bloating, pelvic pain, and frequent urination, and are easily confused with other illnesses Therefore the diagnosis is delayed and the prognosis is poor.<sup>[6]</sup> Subtypes of ovarian tumors reflect a heterogeneous group of diseases, and their determination is relevant for prognosis and treatment prediction. Tumor heterogeneity appears to be very high across subtype and within a single tumor ,major cause of treatment failure.<sup>[7]</sup>

## MATERIALS AND METHODS

After obtaining approval from hospital ethical committee, further procedure was conducted. The present study was conducted at the Department of pathology of rajmata smt Devendra Kumari Singh Deo Govt Medical College Ambikapur.

**Source of Data:** This study will be conducted on surgically resected tumor samples from patients with surface epithelial ovarian tumour received by the Department of Pathology of rajmata smt Devendra kumari singh deo govt medical college ambikapur.

**Methods of Collection of Data**

**Study Design:** Cross-sectional study.

**Period of Study:** April 2021 to march 2023

**Place of Study:** Department of Pathology of rajmata smt Devendra kumari singh deo govt medical college ambikapur.

**Sample Size:** 65 cases of surface epithelial ovarian tumour received during study period.

**Inclusion Criteria**

Every surgically resected tumor specimen of surface epithelial ovarian tumour irrespective of age.

**Exclusion Criteria**

Non-neoplastic lesions, Non-epithelial tumours and metastatic lesions will be excluded.

**Tissue Collection**

After obtaining approval from hospital ethical committee, further procedure was conducted.

**Cross-sectional Study**

On receiving, the specimens were kept in 10% formalin for fixation overnight. A systematic gross examination were performed and findings like external appearance, (solid/papillary/cystic), size, laterality were recorded and specimen were grossed and following thing like capsule, areas of hemorrhage /necrosis and content were noted. Sections from the ovary and other ancillary structure if present (tube, uterus, contralateral ovary and omentum) were taken. Proforma designed to gather uniform necessary information was used for every case. Adequate tissue bits were submitted which were routinely processed manually and paraffin embedded tissue blocks were made. Then the sectioning of tissue blocks were done by rotatory microtome and 4 micron sections were obtained. Then slides were examined under the microscope for presence of epithelial ovarian malignancies.

Statistical analysis was performed by Chi square test, The Fisher’s exact test, Independent sample T test. All statistical test were performed and analyzed by the SPSS software. Statistical significance was determined at p value of <0.05.

**RESULTS**

The present study included 65 patients of surface epithelial ovarian tumor. Among the 65 cases of surface epithelial ovarian tumor were distributed in age group of 19 to 67years. in our study benign mucinous cysadenoma have similar age distribution with serous cystadenoma. higher average age seen in

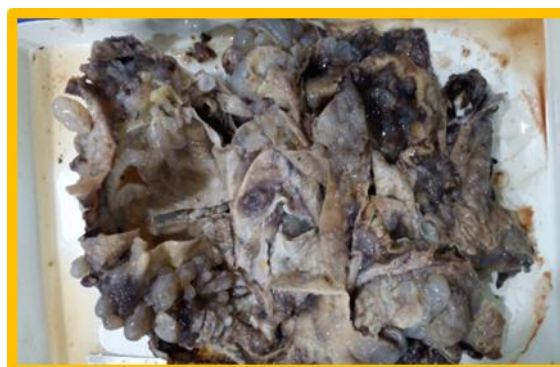mucinous cyst adenoma (43.05) then serous cyst adenoma (39.05).

Surface epithelial ovarian tumour and histopathological subtype. Our study showed serous tumour as most prevalent tumour type among all the surface epithelial tumors. Among 65 cases ,63(96.93) cases were benign, and 2(3%) boderline. Most common benign tumour was serous cyst adenoma in 40 cases followed by mucinous cyst adenoma 23 (35.8%). Similar observation were made by indian auther Choudhary V et al.<sup>[8]</sup>

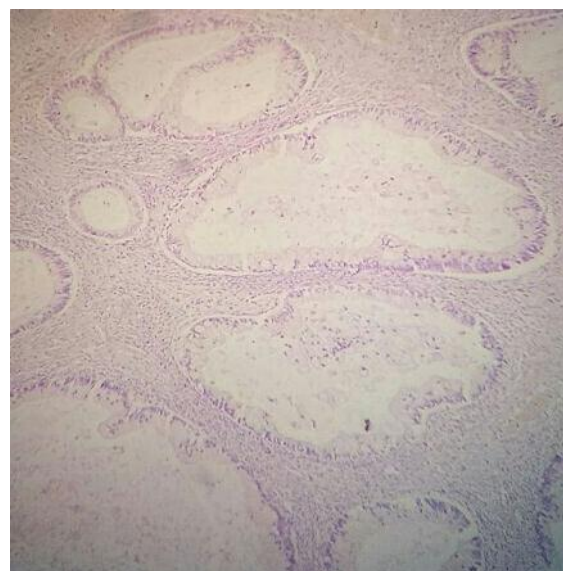
However No significant correlation found in different histological subtype of surface epithelial ovarian tumour with age (P value = >0.05).

**Mode of Clinical Presentation:** Most common emplain of patient was abdominal pain (35.8%) followed by abdominal distention.

**Laterality:** 92 % cases are unilateral. Right side were found more common. only two cases found bilateral.



**Figure 1: gross specimen of Boderline mucinous cyst adenoma**



**Figure 2: 20 X view of boderline mucinous cyst adenoma**

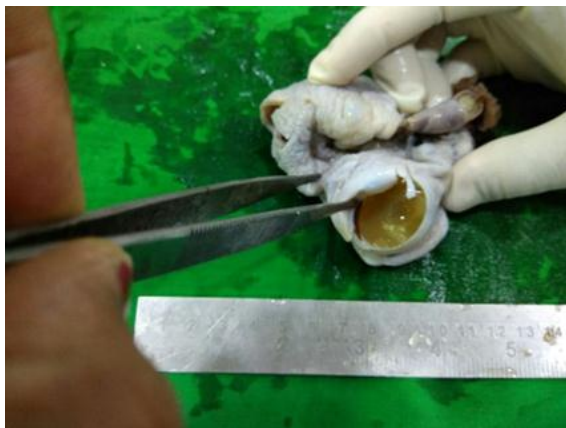**Table 1: Mode of clinical presentation**

Clinical presentation	Frequency	Percentage
Abdominal pain	29	35.8%
Abdominal distension	23	28.3%
Lower abdominal discomfort	15	18.5%
Vaginal bleed	5	6.1%

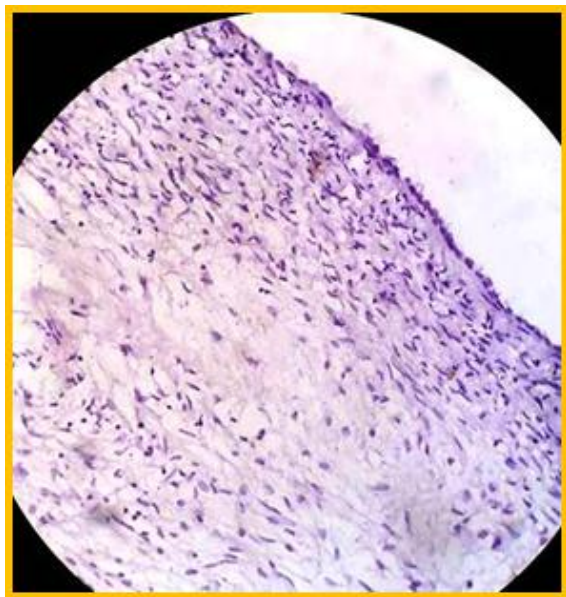
Urinary symptoms	5	6.1%
Dyspepsia	4	4.9%

**Table 2: Serous tumours constitute majority of cases reported followed by mucinous. Histo Logical Type**

Histological type	Benign	Borderline	Malignant	Total
Serous	40	-	-	40
Mucinous	22	1	-	21
Endometrioid	-	-	-	0
Clear cell	-	-	-	0
Seromucinous	1	1	-	2
Brenner	-	-	-	0
Undifferentiated	-	-	-	0
Total	63	2	-	65



**Figure 3: gross specimen of serous cystadenoma**



**Figure 4: 10x view of serous cystadenoma**

## DISCUSSION

Epithelial ovarian cancer is the commonest cause of the gynaecological cancer associated death. Most women have advanced disease, for which the standard of care remain surgery and platinum based cytotoxic chemotherapy.<sup>[9]</sup> Ovarian cancer has historically been called the silent killer with tumour spread in to pelvis and upper abdomen, patients often complain of pelvic or abdominal pain or pressure, abdominal swelling, dyspepsia and early satiety.<sup>[10]</sup> Epithelial ovarian tumour causes nonspecific

symptoms when it is localized to ovary. with the introduction of cisplatin –based-chemotherapy, patient survival has improved overall but the percentage of recurrent disease is so high that more than 80% of patients with advanced stage of the disease die within 5 years even after complete response to chemotherapy.<sup>[11]</sup>

At present, the prognostic characterization of the ovarian cancer patients, based on clinico-pathological parameters such as age, stage, histology grade, FIGO stage seems to be not enough, since patients with similar clinico-pathological feature different clinical outcome. In absence of definite etiological factors and effective tools of screening, the only possible means of improving survival would be to develop effective targeted therapy. This requires a complete understanding of the pathogenesis of ovarian tumors. Many questions relating to the pathogenesis of epithelial ovarian tumours remain unanswered.

The identification of biological factors and its association with tumour aggressiveness and poor outcome could be relevant in order to identify patients with different prognosis and chemotherapy response. It would be of great help to us in selection of patient with higher risk, at time of initial diagnosis. Higher risk patients needed more aggressive therapy or alternative treatment and closer followup. Research based on molecular pathway and hormonal pathway has contributed to improving the knowledge of different subtype of ovarian tumours. It is no longer controversial that the term ovarian cancer subsumes a heterogenous group of malignant tumours that differs with respect to essential features of etiology, pathogenesis, prognosis, pathology, and molecular pathology.<sup>[12]</sup>

Surface epithelial ovarian tumour and histopathological subtype

Our study showed serous tumour as most prevalent tumour type among all the surface epithelial tumors. Among 65 cases, 63(96.93) cases were benign, and 2(3%) borderline. Most common benign tumour was serous cyst adenoma in 40 cases followed by mucinous cyst adenoma 23 (35.8%). Similar observation were made by Indian author Choudhary V et al.<sup>[8]</sup>

In our study benign mucinous cystadenoma have similar age distribution with serous cystadenoma. higher average age seen in mucinous cyst adenoma



(43.05) then serous cyst adenoma (39.05). However No significant correlation found in different histological subtype of surface epithelial ovarian tumour with age (P value = >0.05).

In our study revealed most of the ovarian tumor found associated with unilaterality (96.92%) and only 2 cases (3.1 %) were bilateral. Similar observation were made by Couto F et al,<sup>[13]</sup> 91.2 % unilateral and 8.7 % bilateral, and Chandra K et al.<sup>[14]</sup>

In this study revealed most of the benign ovarian tumor associated with cystic consistency .55 cases of benign tumors found cystic in consistency and 8 cases were partly solid in consistency similar to Kaur et al.<sup>[15]</sup>

Most of benign serous tumor revealed unilocular cyst (35 out of 40). In mucinous tumor multiloculation were common during gross inspection. Similar finding seen in study of Kaur et al.<sup>[15]</sup>

## CONCLUSION

Because of lack of early diagnosis ovarian cancer becomes one of the most lethal ailment in gynecological malignancies. Great heterogeneity in character of epithelial ovarian tumors, individual tumor characteristics can only be associated with different clinical behaviors which may have impact on treatment and prognosis. Clear etiology efficient screening and early diagnosis still yet develop.

## REFERENCES

1. GLOBCAN 2008. Estimated cancer Incidence, Mortality, Prevalence and Disability adjusted life year (dalys) Worldwide in 2008 .<http://globocan.iarc.fr/>. Accessed on 28 .10.2012.
2. Available from: [http://ncrpindia.org/ALL\\_REPORTS/PBCR\\_REPORT\\_2012-2014/index.htm](http://ncrpindia.org/ALL_REPORTS/PBCR_REPORT_2012-2014/index.htm).
3. Kaber RA, Slattery ML .Impact of family history on ovarian cancer risk .the Utah Population database .Arch Intern Med 1995;155:905-12.pmid:<http://www.ncbi.nih.gov/pubmed/7726698>.
4. Murphy NS,Shalini S,Suman G,Pruthvish S,Methew A.Changing trends in incidence of ovarian cancer-The Indian scenario Asian Pac J cancer Prev 2009;10:1025-30.
5. Key changes to the World Health Organization (WHO) classification of female genital tumors introduced in the 5 th edition (2020) Mc Cluggage WG, Singh N, Gilks CB. Histopathology.2022;80:762-778.[Pub Med] [Google Scholar]
6. Gregg S, Genuardi M, Benedetti-Panici P, Cento R, Scambia C, Neri G, Mancuso S. Analysis of 138 consecutive ovarian cancer patients. Incidence and characteristics of familial cases. Gynaecol Oncol 1990, 39: 300
7. Kossai M, Leary A, Scoazec J Y, Genestie C. Ovarian Cancer: A Heterogenous disease.Pathobiology.2018;85(1-2):49.doi:10.1159/000479006.Epub2017oct12.PMID:29020678.
8. Choudhary V ,Somani S, Koul R .Evaluation of benign ovarian tumour in tertiary care center .Indian Journal of obstetrics and gynecology Research 2016;3(4):383-387.
9. Jayson GC, Kohn EC ,Kitchener HC , Leadermann JA . Ovarian cancer .[http://dx.doi.org/10.2016/so140-6736\(13\)62146-7](http://dx.doi.org/10.2016/so140-6736(13)62146-7).
10. Jelovac D , Armstrong .DK , Recent progress in the diagnosis and the treatment of ovarian cancer. CA cancer J Clinic.2011;61(3):183-203.doi:10.3322/caac.20113.
11. Greshenson DM ,Copeland LJ , Kavanagh JJ , Stringer CA , Soul PB ,Wharton JT .Treatment of metastatic stromal tumours of the ovary with cisplatin , doxorubicin and cyclophosphamide . Obstet Gynecol .1987 Nov ;70(5):765-9.
12. Meinhold-Heerlein I ,Hauptmann S (2014)The heterogeneity of ovarian cancer .Arch Gynecol Obstet 289:237-239.
13. Couto F .Nadkarni NS , Rebello MJ .Ovarian tumours in goa : a clinic pathological study of ovarian tumours . J Obstet Gynaecol India .1993;43(3):408-12.
14. Chandra K ,Arora N . Clinicopathological analysis of ovarian tumours : a two year retrospective study .Int J Reprod Contracept Obstet Gynecol .2019 Aug ;8(8):3015-3020.
15. Kaur D, Agarwal P . To study the relationship of parity and laterality with different ovarian lesion. IP Journal of Diagnostic Pathology and Oncology .Jun 2021 , vol 6 ,issue 2, 135-137.